

LATERAL PERIODONTAL CYST: CASE REPORT  
CISTO PERIODONTAL LATERAL: RELATO DE CASO

Gracielle Rodrigues Tavares\*  
Júlia Magalhães da Costa Lima\*  
Sócrates Steffano da Silva Tavares\*\*  
Eduardo Dias-Ribeiro\*\*\*  
Cláudia Roberta Leite Vieira de Figueiredo\*\*\*\*  
Maria do Socorro Aragão\*\*\*\*

ABSTRACT

Although the majority of cystic jaw lesions are well studied, discussed and defined, the Lateral Periodontal Cyst is a relatively uncommon lesion and its etiology has not been yet clarified. For the rarity of the lesion, a case of Lateral Periodontal Cyst is reported with focus on clinical, radiographic and microscopic aspects.

DESCRIPTORS: Odontogenic cysts • Periodontal cyst • Pathology, oral.

RESUMO

Apesar da maioria das lesões císticas maxilares serem bem estudadas, discutidas e definidas, o Cisto Periodontal Lateral é uma lesão relativamente incomum e ainda não tem sua etiologia esclarecida. Pela raridade da lesão, um caso clínico de Cisto Periodontal Lateral é relatado com enfoque nos aspectos clínicos, radiográficos e microscópicos.

DESCRIPTORIOS: Cistos odontogênicos • Cisto periodontal • Patologia bucal.

\*DDS, MSc, Department of Stomatology, Paraíba Federal University, João Pessoa, Paraíba, Brazil.

\*\*DDS, Oral and Maxillofacial Surgery Service, Paraíba Estadual University, Campina Grande, Paraíba, Brazil.

\*\*\*DDS, MSc, Department of Stomatology, Bauru Dental School, University of São Paulo, Bauru, Brazil.

\*\*\*\*DDS, MSc, PhD, Department of Oral Pathology, Paraíba Federal University, João Pessoa, Paraíba, Brazil.

According to the World Health Organization (WHO), the Lateral Periodontal Cyst (LPC) is a rare type of odontogenic cyst of development, which is adjacent or lateral in the root of a tooth with vitality (Méndez *et al.*<sup>1</sup> 2007; Neville *et al.*<sup>2</sup> 2004; Pereira *et al.*<sup>3</sup> 2006; Formoso Senande *et al.*<sup>4</sup> 2008).

It represents less than 2% of all cysts of the jaw bones (Lima *et al.*<sup>5</sup> 2005; Neville *et al.*<sup>2</sup> 2004; Pereira *et al.*<sup>3</sup> 2006). Around 1.5% of all jaw cysts are diagnosed as lateral periodontal cyst (Kerezoudis *et al.*<sup>6</sup> 2000; Senande *et al.*<sup>4</sup>, 2008). Due to the low frequency of this cyst, its biological behavior, especially in relation to the potential for growth and effects on adjacent teeth, is uncertain (Carter *et al.*<sup>7</sup> 1996).

A study by Calvet and Quadros<sup>8</sup> (2002), using 276 records with the objective of verifying the prevalence of odontogenic cysts of development, found that the lateral periodontal cyst corresponded to 1.1% of cases.

Three hypotheses seek to explain the histogenesis of this cyst that is still uncertain. It may arise from the reduced epithelium of the enamel, along the lateral surface of the tooth root (Mendes and van der Waal<sup>9</sup> 2006; Lima *et al.*<sup>5</sup> 2005); from the epithelial rests of Malassez in the periodontal ligament; or from the proliferation of rests from the dental lamina (Lima *et al.*<sup>5</sup> 2005; Mendes and van der Waal<sup>9</sup> 2006; Neville *et al.*<sup>2</sup> 2004; Pereira *et al.*<sup>3</sup> 2006).

Clinical symptoms are usually absent and the diagnosis is made through routine radiographic examination (Lima *et al.*<sup>5</sup> 2005; Méndez *et al.*<sup>1</sup> 2007; Neville *et al.*<sup>2</sup> 2004; Regezzi and Sciubba<sup>10</sup> 2000). It is often found in individuals between the fifth and seventh decades of life, and it is rarely observed before 30 years of age (Kerezoudis *et al.*<sup>6</sup> 2000; Méndez *et al.*<sup>1</sup> 2007; Formoso Senande *et al.*<sup>4</sup> 2008).

It affects individuals of both genders (Carter *et al.*<sup>7</sup> 1996; Mendes and van der Waal<sup>9</sup> 2006), although there is a predilection for males (Formoso Senande *et al.*<sup>4</sup> 2008; Pereira *et al.*<sup>3</sup> 2006). In a research conducted by Formoso Senande *et al.*<sup>4</sup> (2008) there was a slight predominance of LPC in males, in the proportion of 6:5.

Rasmusson *et al.*<sup>11</sup> (1991) studied 32 cases of lateral periodontal cyst in which it was observed 22 cases in men and 10 in women.

The most common site is between canines and lower pre-molars (Carter *et al.*<sup>7</sup> 1996; Neville *et al.*<sup>2</sup> 2004; Pereira *et al.*<sup>3</sup> 2006; Uçok *et al.*<sup>12</sup> 2005; Chbicheb *et al.*<sup>13</sup> 2008). When it occurs in the maxilla, there is a predilection for the same region (Méndez *et al.*<sup>1</sup> 2007). Formoso Senande *et al.*<sup>4</sup> (2008) observed in their studies a higher prevalence of lateral periodontal cyst in the maxilla (72%).

The radiographic characteristics of the LPC can be observed in other odontogenic lesions, for example, an odontogenic ceratocyst, and therefore it is not sufficient for the diagnosis (Neville *et al.*<sup>2</sup> 2004). It is observed a radiolucent image, surrounded by a radiopaque line, located laterally to the root of a tooth with vitality (Chbicheb *et al.*<sup>13</sup> 2008; Neville *et al.*<sup>2</sup> 2004). It presents about 1 cm in its largest diameter, but some are large and may compromise the full development of the root of the tooth involved (Lima *et al.*<sup>5</sup>, 2005; Méndez *et al.*<sup>1</sup>, 2007; Neville *et al.*<sup>2</sup>, 2004; Regezzi and Sciubba<sup>10</sup>, 2000; Formoso Senande *et al.*<sup>4</sup> 2008).

The histopathological findings showed a capsule of a thin fibrous connective tissue (1 to 5 layers of cells), without inflammation, with foci of clear cells rich in glycogen (Lima *et al.*<sup>5</sup> 2005; Mendes and van der Waal<sup>9</sup> 2006; Neville *et al.*<sup>2</sup> 2004; Pereira *et al.*<sup>3</sup> 2006; Chbicheb *et al.*<sup>13</sup> 2008; Saygun *et al.*<sup>14</sup> 2001), similar to cells found in the remnants of the dental lamina (Lima *et al.*<sup>5</sup> 2005; Pereira *et al.*<sup>3</sup> 2006). Presence of separation of the epithelium of the subjacent connective tissue, resulting in a crack, and thickened epithelium or "signs" that sometimes produce mural protuberances or intraluminal protusions (Carter *et al.*<sup>7</sup> 1996; Lima *et al.*<sup>5</sup> 2005; Mendes and van der Waal<sup>9</sup> 2006; Saygun *et al.*<sup>14</sup> 2001).

The treatment of choice is surgical removal by enucleation and curettage, with subsequent histological evaluation to confirm the diagnosis (Lima *et al.*<sup>5</sup> 2005; Méndez *et al.*<sup>1</sup> 2007; Formoso Senande *et al.*<sup>4</sup> 2008).

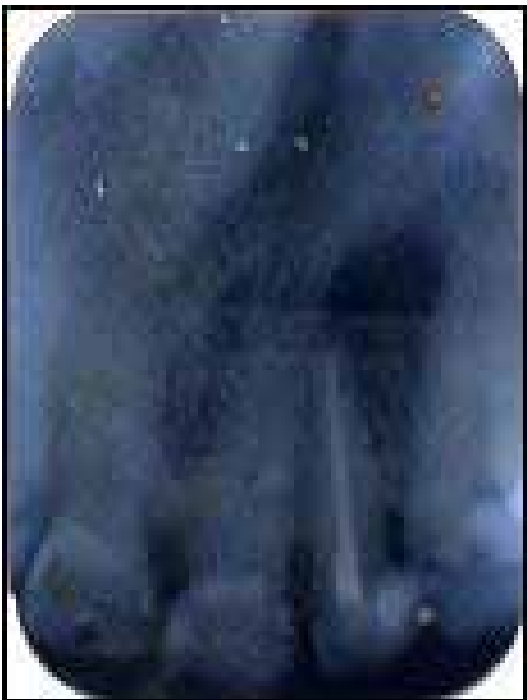

Recurrence is rare (Lima *et al.*<sup>5</sup> 2005; Neville *et al.*<sup>2</sup> 2004; Regezzi and Sciuba<sup>10</sup> 2000; Formoso Senande *et al.*<sup>4</sup> 2008) and, when it occurs, is usually associated with multilocular lesions (Lima *et al.*<sup>5</sup> 2005; Méndez *et al.*<sup>1</sup> 2007).

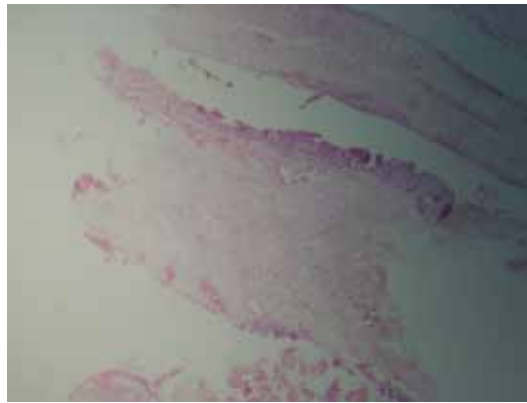
The aim of this paper is to report a clinical case of lateral periodontal cyst from the clinical, radiographic and histopathologic aspects, emphasizing the need for histopathological examination, for its radiographic similarity with other odontogenic lesions, the odontogenic ceratocyst, for example, that requires different treatment and has an aggressive behavior.

#### CASE REPORT

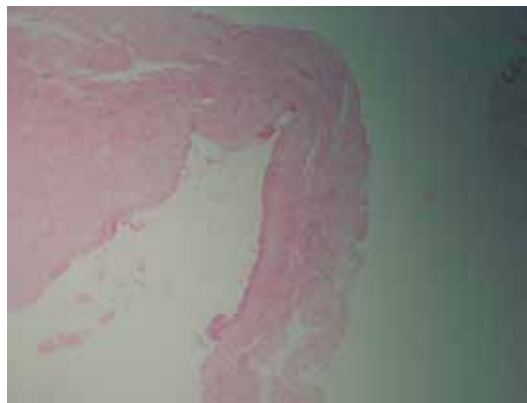
Female patient, 45 years old, leucoderma, complained of increase in volume in the left side of the jaw, without any reference to pain or other discomfort. At physical examination, it was observed an increase in volume and crackle in the region of upper lateral left incisor. There were no signs of inflammatory process and, on palpation, it had a firm and painless consistency. On examination of the periapical radiograph (Figure 1) there was a radiolucent area, well defined, between the 22 and 23 elements, causing displace-



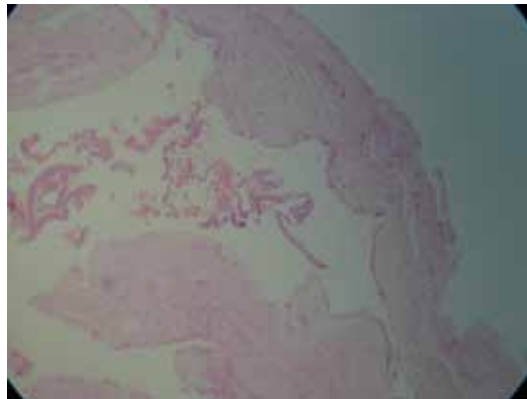
**Figure 1** - Radiographic picture of radiolucent lesion between the 22 and 23 elements.



**Figure 2** - A cystic lesion with thin capsule of fibrous connective tissue.

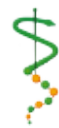

**Figure 3** - A thin epithelium with one to three layers of cells flattened.



**Figure 4** - The lumen of the cavity is filled by red blood cells and peeled epithelial cells.

ment of the root of the element 22 in the mesial direction. After clinical and radiographic evaluation performed by the first professional sought by the patient, with presumptive diagnosis of periapical cyst, the element 22 was subjected to endodontic treatment. Even after endodontic treatment there was no regression of the lesion. The patient sought for other professional, made further tests and was submitted to enucleation of the lesion. The material was sent for histopathological analysis.



During surgery it was observed the presence of cystic fluid and a friable capsule.

At macroscopic examination the surgical piece was described as a lesion of soft tissue, dark brown colour, fibrous consistency, with dimensions of 2.3mm x 1mm x 0.3mm. The lesion was hemisectioned presenting a cavity and the same macroscopic characteristics mentioned in its interior.

At microscopic examination, the histological sections stained with Hematoxylin-Eosin showed a cystic lesion with thin capsule of fibrous connective tissue in most regions (Figure 2). The capsule was not inflamed and was lined by a thin epithelium with one to three layers of cells flattened in its largest extension (Figure 3). However, there were focal areas of nodular thickening of the limiting epithelial, with cells with the appearance of swirl. The lumen of the cavity is partly filled by red blood cells and peeled epithelial cells (Figure 4).

After the histopathological examination the final diagnosis was of lateral periodontal cyst.

#### DISCUSSION

The lateral periodontal cyst is a rare odontogenic cyst representing less than 2% of all cysts of the jaw bones (Lima *et al.*<sup>5</sup> 2005; Neville *et al.*<sup>2</sup> 2004; Pereira *et al.*<sup>3</sup> 2006). This view is shared by Kerezoudis *et al.*<sup>6</sup> (2000); Calvet and Quadros<sup>8</sup> (2002); Formoso Senande *et al.*<sup>4</sup> (2008).

It is developed adjacent to the root of a vital tooth (Méndez *et al.*<sup>1</sup> 2007; Neville *et al.*<sup>2</sup> 2004; Pereira *et al.*<sup>3</sup> 2006; Formoso Senande *et al.*<sup>4</sup> 2008). In the clinical case concerned, the lateral periodontal cyst is located laterally to an endodontically treated tooth, however, this tooth, when vital, already had the injury and was endodontically treated because it was wrongly thought of being a periapical cyst. Therefore, this lesion was adjacent to a vital tooth, corroborating with the cited authors. Wrong diagnosis can result in unnecessary procedures such as: endodontic treatment, periodontal procedures, tooth extraction or aggressive surgical excision (Carter *et al.*<sup>7</sup> 1996).

The histogenesis of this cyst is still uncertain and may arise from the reduced epithelium of the enamel, along the lateral surface of the root of the tooth; from the epithelial rests of Malassez in the periodontal ligament; or from the proliferation of remnants of dental lamina (Lima *et al.*<sup>5</sup> 2005; Mendes and van der Waal<sup>9</sup> 2006; Neville *et al.*<sup>2</sup> 2004; Pereira *et al.*<sup>3</sup> 2006). Because in most cases it is limited by a narrow non-keratinized and non-inflammatory epithelium, it is believed that its origin is in the reduced epithelium of the enamel (Mendes and van der Wall<sup>9</sup> 2006; Lima *et al.*<sup>5</sup> 2005). Moreover, the fact that it occurs in the crest of the alveolar ridge and presents clear cells, rich in glycogen in the epithelial plate, make the theory of the origin of the LPC in the dental lamina more plausible, because clear cells are also found in the remnants of the dental lamina (Lima *et al.*<sup>5</sup> 2005; Pereira *et al.*<sup>3</sup> 2006).

Some studies found no gender predilection (Carter *et al.*<sup>7</sup> 1996; Mendes and van der Waal<sup>9</sup> 2006) others, however, showed a predilection for males (Rasmussen *et al.*<sup>11</sup>, 1991; Kerezoudis *et al.*<sup>6</sup> 2000; Pereira *et al.*<sup>3</sup> 2006; Formoso Senande *et al.*<sup>4</sup> 2008). In this case, the LPC was developed in a woman.

Regarding the preferential location of occurrence of LPC, relevant reports in the literature mention the areas of canine-lateral incisor and mandibular pre-molars as being the most affected (Kerezoudis *et al.*<sup>6</sup> 2000; Lima *et al.*<sup>5</sup> 2005; Neville *et al.*<sup>2</sup> 2004). In contrast, this case occurred in the maxilla, corroborating the findings of Senande *et al.*<sup>4</sup> (2008).

The diagnosis occurs randomly through routine radiographic examinations, as the majority of these lesions are asymptomatic (Kerezoudis *et al.*<sup>6</sup> 2000; Lima *et al.*<sup>5</sup> 2005; Méndez *et al.*<sup>1</sup> 2007; Formoso Senande *et al.*<sup>4</sup> 2008). In this case, however, the patient sought dental care due to increased volume in the affected area, although she does not feel pain.

The LPC has been described as an intraradicular radiolucency, well defined, circular to oval in shape, often in the form of a "drop of tear" that may have sclerotic edges (Carter *et al.*<sup>7</sup> 1996; Pereira *et al.*<sup>3</sup>



2006). The radiographic findings of this lesion were most consistent with this description.

The differential diagnosis of LPC should be done with entities such as the gingival cyst of adults, inflammatory processes of periodont or periapical, when infected; primary cyst, infrabony pockets, ameloblastoma in early stage, malignant lesions in the initial phase and residual cyst in edentulism patients (Pereira *et al.*<sup>3</sup> 2006).

The LPC presented in this study had approximate size of 2.5 mm, corroborating some studies. In the study of 32 cases Rasmussen *et al* reported that the size of the LPC varies between 2.5 and 15 mm with an average of 3 to 7 mm. Cohen *et al.* also stated that the lesion is small with a diameter of up to 10 mm (Carter *et al.*<sup>7</sup> 1996).

The histological findings of the LPC are unique and differentiated it from other interradicular cysts. These cysts are characteristically lined by a non-proliferative thin layer, non-keratinized, of stratified cuboidal epithelium with approximately 3 to 6 layers of cells. They show focal areas of nodular thickening representing boards, and clear cells rich in glycogen (Carter *et al.*<sup>7</sup> 1996; Pereira *et al.*<sup>3</sup> 2006; Lima *et al.*<sup>5</sup> 2005). The histological aspects seen in

this case were in line with those described in the literature, where the diagnosis of LPC was confirmed by analysis of the clinical, radiographic characteristics and the histopathological aspects.

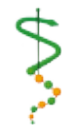The treatment of total excision of the cyst was recommended by the literature and the recurrence rate is low, tending to zero (Lima *et al.*<sup>5</sup> 2005; Pereira *et al.*<sup>3</sup> 2006). Despite this low recurrence, the lesions should be removed and the patient must be radiographically followed for a few years, since the possibility of neoplastic transformation in LPC is similar to other odontogenic cysts, including the development of mural ameloblastoma and squamous cell carcinoma (Carter *et al.*<sup>7</sup> 1996).

#### CONCLUSIONS

- The vitality of pulpal dental elements involved and the gingival conditions should always be checked.
- Avoid injury to the teeth with pulp vitality and try to remove the piece in full to avoid recurrence during surgical excision.
- For the definitive diagnosis of LPC the anatomo-pathological examination of surgical specimen is fundamental.

#### REFERENCES

1. Méndez P, Junquera L, Gallego L, Baladrón J. Botryoid odontogenic cyst: clinical and pathological analysis in relation to recurrence. *Med Oral Patol Oral Cir Bucal* 2007 Dec; 12(8): E594-8.
2. Neville BW, Damm DD, Allen CM, Bouquet JE. Patologia oral e maxillofacial. 2 ed. Rio de Janeiro: Guanabara Koogan, 2004. 798p.
3. Pereira AM *et al.* Cisto periodontal lateral em localização pouco usual. *Odontol Clín-Cient* 2006 jan-mar; 5(1): 75-81.
4. Formoso Senande MFF, Figueiredo R, Berini Aytés L, Gay Escoda C. Lateral periodontal cysts: A retrospective study of 11 cases. *Med Oral Patol Oral Cir Bucal* 2008 May; 13(5): E313-7.
5. Lima AAS, Machado MAN, Braga AMC, Souza MH. Lateral periodontal cyst: aetiology, diagnosis and clinical significance. A review and report of case. *Rev Clin Pesq Odontol* 2005 abr/jun; 1(4): 55-59.
6. Kerezoudis NP, Donta-Bakoyianni C, Siskos G. The lateral periodontal cyst: aetiology, clinical significance and diagnosis. *Endod Dent Traumatol* 2000 Aug; 16(4): 144-50.



7. Carter LC, Carney YL, Perez-Pudlewski D. Lateral periodontal cyst. Multifactorial analysis of a previously unreported series. *Oral Surg Oral Med Oral Pathol Oral Radiol Endod* 1996 Feb; 81(2): 210-6.
8. Calvet C, Quadros O. Estudo da prevalência de cistos odontogenicos de desenvolvimento. *Rev Fac Odontol Porto Alegre* 2002 jul; 43(1): 8-14.
9. Mendes RA, van der Waal I. An unusual clinicoradiographic presentation of a lateral periodontal cyst – report of two cases. *Med Oral Patol Oral Cir Bucal* 2006; 11: E185-7.
10. Regezzi JA, Sciubba JJ. Patologia bucal: correlações clinicopatológicas. 3 ed. Rio de Janeiro: Guanabara Koogan, 2000. 475p.
11. Rasmusson LG, Magnusson BC, Borrmann H. The lateral periodontal cyst. A histopathological and radiographic study of 32 cases. *Br J Oral Maxillofac Surg* 1991 Feb; 29(1): 54-7.
12. Uçok Ö *et al.* Botryoid odontogenic cyst: report of a case with extensive epithelial proliferation. *Int J Oral Maxillofac Surg* 2005 Sep; 34(6): 693-5.
13. Chbicheb S, Bennani A, Taleb B, Wady WE. Kyste odontogène botrióide. *Rev Stomatol Chir Maxillofac* 2008 Apr; 109(2): 114-6.
14. Saygun I, Özdemir A, Safali M. Lateral periodontal Cyst. *Turk J Med Sci* 2001; 31: 375-8.

Recebido em: 03/05/2010

Aceito em: 09/08/2010

